



# The FALD-V: A predictive formula for preoperative volume assessment of adipose tissue transplantation in FALD flap

Benedetto Longo <sup>a,\*</sup>, Gennaro D'Orsi <sup>b</sup>, Alessio Farcomeni <sup>c</sup>,  
Angelica Pistoia <sup>a</sup>, Martina Giacalone <sup>a</sup>, Elettra Gagliano <sup>a</sup>,  
Lisa Vannucchi <sup>a</sup>, Gianluca Vanni <sup>d</sup>, Claudio Oreste Buonomo <sup>d</sup>,  
Valerio Cervelli <sup>a</sup>

<sup>a</sup> Department of Surgical Sciences, School of Medicine and Surgery, Tor Vergata University of Rome, Rome, Italy

<sup>b</sup> PhD School of Applied Medical-Surgical Sciences, University of Rome Tor Vergata, Via Montpellier 1, 00133 Rome, Italy

<sup>c</sup> Department of Economics & Finance, Tor Vergata University of Rome, Rome, Italy

<sup>d</sup> Division of Breast Unit, Department of Surgical Sciences, School of Medicine and Surgery, Tor Vergata University of Rome, Rome, Italy

Received 11 October 2023; Accepted 29 January 2024

## KEYWORDS

FALD flap;  
Predictive formula;  
Breast reconstruction;  
Autologous breast reconstruction;  
Latissimus dorsi flap;  
Fat grafting

**Summary** *Background:* The fat-augmented latissimus dorsi (FALD) flap is an evolution of the traditional latissimus dorsi (LD) flap, which allows to obtain a total autologous breast reconstruction (BR) avoiding the use of breast implants. The aim of this study was to develop a predictive preoperative formula in order to estimate and optimize the amount of fat to be transferred during FALD flap BR, using only anthropometric measurements.

*Methods:* We conducted a prospective clinical study between September 2020 and April 2023. All patients underwent back pre-operative ultrasound scan to assess the subcutaneous skin paddle thickness (SPT) and a regression analysis was performed to evaluate which anthropometric variable had a better correlation with this thickness.

*Results:* Data from 66 FALD flaps were collected. The mean SPT was 11.95 mm (SD 4.56). A significant correlation between SPT and body mass index (BMI) was found ( $r = 0.640$ ,  $p < 0.0001$ ). Using the fat-to-capacity ratio (113%), the following formula (the FALD-V) was developed to predict the needed fat transfer into FALD flap:  $[-509 + 12.32 \times \text{BMI} + 11.71 \times \text{skin paddle width} + 17.43 \times \text{skin paddle height}] \times 1.13$ .

\* Correspondence to: Department of Surgical Sciences, School of Medicine and Surgery, Tor Vergata University of Rome, Via Montpellier, 1, 00133 Roma, Italy.

E-mail address: [benedetto.longo@uniroma2.it](mailto:benedetto.longo@uniroma2.it) (B. Longo).

The considered variables (BMI, skin paddle width and skin paddle height) were statistically significant ( $p < 0.001$ ,  $p = 0.0483$ ,  $p = 0.0154$ , respectively). The cross-validation confirmed the accuracy of the formula ( $r = 0.810$ ).

**Conclusion:** The FALD-V can be used as an innovative complimentary device in the planning of FALD flap one-stage total autologous BR. To enhance its application, a 3.0 WebApp at [www.braflap.com](http://www.braflap.com) (and [www.breast-v.com](http://www.breast-v.com)) is available free of charge for both iOS and Android devices.

**Level of evidence:** II

© 2024 British Association of Plastic, Reconstructive and Aesthetic Surgeons. Published by Elsevier Ltd.

## Introduction

The latissimus dorsi (LD) flap is a well-known procedure for autologous breast reconstruction (BR) that can be utilized to address a large spectrum of breast cancer surgery defects.<sup>1-3</sup> The introduction of fat-augmented latissimus dorsi (FALD) flap allowed plastic surgeons to perform totally autologous BRs of small and medium sized breasts, avoiding the use of breast implants, combining the LD flap with immediate intraoperative autologous fat transfer (AFT).<sup>4-6</sup> As described in previous studies, AFT should be safely performed orthotopically into the subcutaneous tissue of the skin paddle of the flap, above and below the Scarpa's fascia.<sup>4</sup> It is generally not recommended to inject fat tissue directly into the muscle, because it could lead to potentially fatal embolization, in addition to potential risks of skin flap impairment due to direct vascular injury.<sup>7-10</sup> Practicing this innovative procedure, plastic surgeons can use a simple method to obtain an autologous reconstruction without necessarily recurring to microsurgery.<sup>11-14</sup> However, accurate pre-operative breast evaluation and intra-operative flap tailoring are key determinants for the final esthetic outcome of the reconstruction.<sup>15-18</sup> A 3.0 WebApp for IOS and Android devices available for free at [www.BREAST-V.com](http://www.BREAST-V.com) and [www.braflap.com](http://www.braflap.com) comes in handy for the pre-operative selection of appropriate patients, since the FALD flap is indicated for reconstructions of small (< 400 cc) and medium-sized (401-600 cc) breasts.<sup>19-21</sup> A central element of this BR is knowing how much fat the reconstructive surgeon has to infiltrate into the skin-adipose paddle of the flap, trying to avoid unwarranted infiltrations that could compromise its correct perfusion and also to avoid unnecessary time for adipose tissue collection.<sup>22</sup>

In 2014, Del Vecchio et al. in an elegant study defined graft-to-capacity ratio as the volume of grafted fat in relation to the volume of the recipient site, analyzing its clinical importance in cases of large-volume fat transplantation.<sup>23</sup> The calculated average graft-to-capacity ratio was 113%, with a standard deviation of 22%. Based on this ratio, knowing the precise volume of the skin-adipose paddle above the LD muscle, it is possible to calculate preoperatively the precise amount of AFT needed to infiltrate. In this study, we investigated possible associations between anthropometric values and subcutaneous fat thickness of the back, using this relationship to assess the volume of the skin-adipose paddle of the LD flap, and consequently the volume of fat needed to infiltrate into it. The aim of our research was to develop a

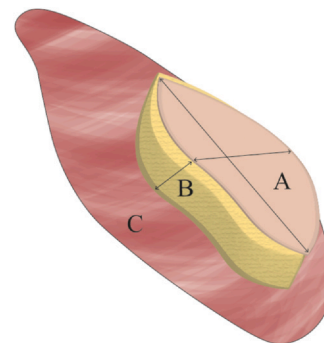
mathematical formula that would allow us to predict and optimize the amount of AFT needed to infiltrate during FALD flap BR to achieve a one-stage autologous BR enhancing surgical planning and operative time (OT).

## Patients and Methods

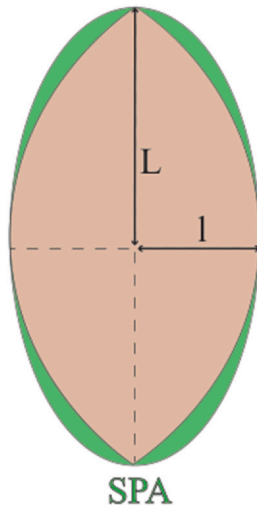
Between September 2020 and April 2023, we prospectively enrolled patients scheduled for FALD flap BR at our institute, the Policlinico Tor Vergata University Hospital, for a prospective clinical study, in accordance with the tenets of the Declaration of Helsinki. All patients underwent pre-operative ultrasound scan to evaluate subcutaneous skin paddle thickness (SPT) of the back.

Data were collected prospectively evaluating age, height, weight, body mass index (BMI), skin paddle size (width and height), skin paddle area (SPA), SPT, skin paddle volume (SPV), predicted intraoperative AFT volume, true intraoperative AFT volume, OTs and complications. The calculated SPT, SPV and the predicted AFT volume remained blinded to the first surgeon during the study.

The preoperative drawing consists of an ellipse of skin placed in one half of the back, typically measuring between 9 and 12 cm in height using pinch test. The skin-adipose paddle over the LD muscle represents the main volumetric component of the FALD flap, and has a three-dimensional structure, composed of a width and height of the cutaneous ellipse and a depth of the adipose subcutaneous tissue (Figure 1). During the dissection of the thoracodorsal



**Figure 1** Showed the three-dimensional structure of the skin paddle over the LD muscle. A = skin paddle over LD muscle; B = subcutaneous tissue of skin paddle; C = LD muscle.



**Figure 2** The skin paddle area (SPA) is likened to the area of an ellipse (green) and is easily calculated multiplying  $L \times l \times \pi$ , where “L” is the length of the semi-major axis and “l” is the length of semi-minor axis.

pedicle, we preserve the thoracodorsal nerve intact in order to avoid long-term atrophy of the LD muscle. After flap harvest and accurate pedicle dissection, the flap is rotated through a subcutaneous tunnel to the anterior chest wall without tension (Video 1). Adipose tissue is harvested using 2.4 mm cannulas and 10 ml syringes, subsequently centrifuged at 3000 rpm for 3 min according to Coleman’s technique. The AFT is performed above and especially below the Scarpa’s fascia of the skin paddle, through 1 ml syringes and 1.2 mm cannulas (Video 2).

Supplementary material related to this article can be found online at [doi:10.1016/j.bjps.2024.01.014](https://doi.org/10.1016/j.bjps.2024.01.014).

### Skin paddle area (SPA)

The SPA is likened to the area of an ellipse and is easily calculated by measuring its width and height [Figure 2] and applying a mathematical formula (Ellipse area =  $L \times l \times \pi$ ; where “L” is the length of the semi-major axis and “l” is the length of semi-minor axis) as follow:

$$\text{SPA (cm}^2\text{)} = \text{skin paddle width}/2 \times \text{skin paddle height}/2 \times \pi \quad (3.14)$$

### Skin paddle thickness (SPT)

While in the case of SPA calculation is needed to apply easily preoperative measurements to a mathematical formula only, for the prediction of SPT the procedure is more demanding.

An ultrasound scan with a linear probe has been used to exactly assess the skin and subcutaneous tissue thickness until LD muscle fascia. It represents a simple, quick, non-invasive and easily reproducible procedure to measure the depth of the tissues. The ultrasound scan was performed the day before surgery, placing the linear probe (8 MHz)

accurately in the central point of the skin paddle drawn on the back. The probe was only lightly placed on the skin with the patient in prone decubitus position and the arms positioned along the body. Care has been taken not to press the probe excessively on the skin so as not to alter the calculated thickness. Figure 3 illustrates this measurement during an ultrasound examination, with the different anatomical structures clearly noticeable.

### Statistical analysis

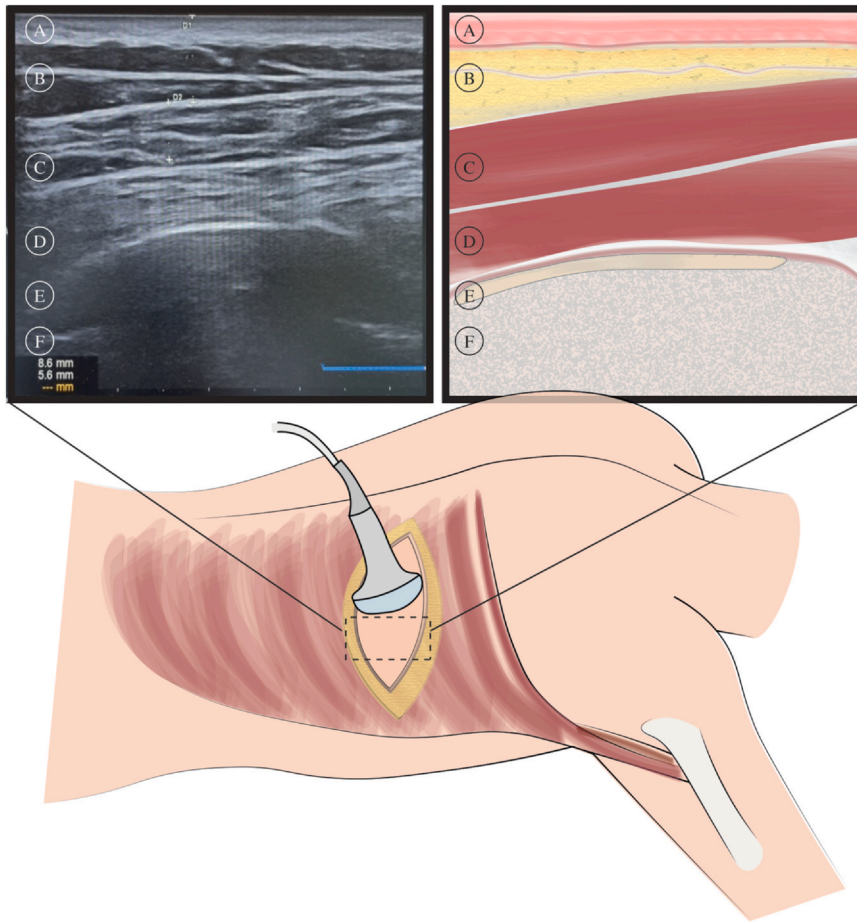
Data are expressed as mean  $\pm$  standard deviation or median  $\pm$  median absolute deviation (MAD) where appropriate. Association between numerical variables was assessed by means of Pearson or Spearman correlation, where appropriate. Linear regression was used to predict relevant endpoints, after assessing their normality. Non-linear regression was also used by pre-specifying the parameter-driven non-linear relationship of interest. All tests are two-tailed, and a significance level of 5% was fixed before the analysis. Analyses were conducted using the R software, version 4.1.2.

### Results

A total of 66 FALD flaps (61 patients) were performed during the time period examined. The mean age was 54.05 years (SD 9.38), while the average BMI was 24.09 kg/m<sup>2</sup> (SD 3.78). The procedure was unilateral in 56 cases (91.8%) and bilateral in 5 cases (8.2%). The timing of reconstruction was immediate for 33 (50%) breasts and delayed for the other 33 (50%) breasts. Regarding the immediate cases, Madden’s Modified Radical Mastectomy was performed on 4 (12.1% of the immediate BR) breasts, Skin Sparing Mastectomy on 15 (45.4% of the immediate BR) breasts, and Nipple-Sparing Mastectomy (NSM) on 14 (42.4% of the immediate BR) breasts. The mean operating time was 266.63 min (SD 82.56). No case of total or partial FALD flap necrosis occurred, while there were 4 cases of fat necrosis (6.06%) detected on postoperative ultrasound examination. Concerning general complications, 7 cases (10.61%) of persistent seroma at the donor site occurred. All these cases have been solved using needle aspiration in outpatient setting. One infection (1.51%) occurred at the reconstructed breast, resistant to antibiotic treatment and requiring surgical revision. We report no case of hematoma and chronic pain in our series. The average skin paddle width was 19.04 cm (SD 1.59) and skin paddle height 9.67 cm (SD 1.22). The average calculated SPA was 145.12 cm<sup>2</sup> (SD 26.41). Regarding data extrapolated from the ultrasound investigation, the mean SPT was 11.95 mm (SD 4.56), the maximum thickness was 25.5 mm, while the minimum 4.8 mm.

### Skin paddle volume (SPV) calculation

Simple regression analysis showed that BMI has significant correlation with subcutaneous thickness ( $r = 0.640$ ,  $p < 0.0001$ ) (Figure 4). As a result, this final predictive



**Figure 3** The linear probe was only lightly placed on the skin with the patient in prone decubitus position and the arms positioned along the body. A = skin; B = subcutaneous adipose tissue; C = LD muscle; D = paraspinal and underlying muscles; E = periosteum; F = costal bone.

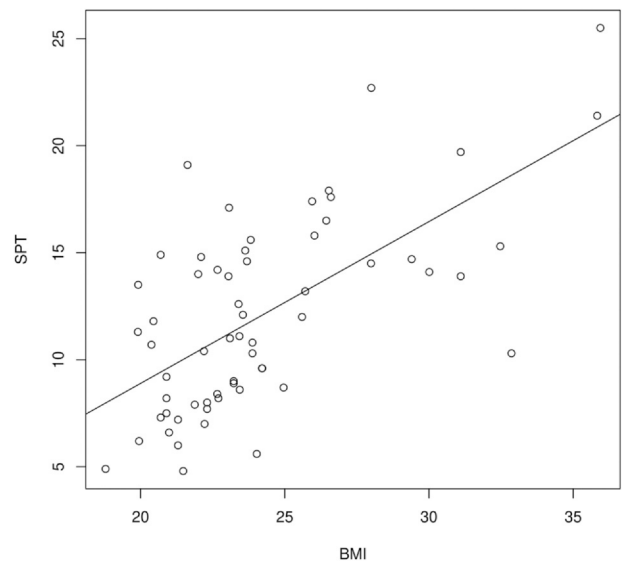
formula provided the best model to determine the three-dimensional volume of the whole skin paddle of the flap:

$$SPV = -509 + 12.32 \times BMI + 11.71 \times \text{skin paddle width} + 17.43 \times \text{skin paddle height}$$

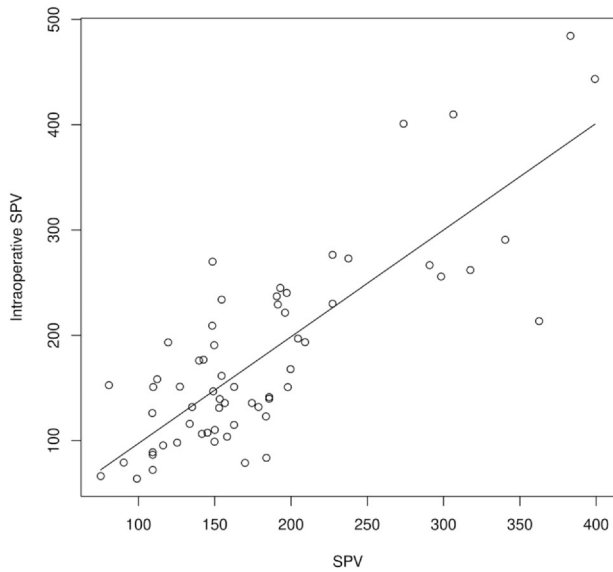
The average calculated three-dimensional volume of the skin paddle was 179.33 cc (SD 71.88). In order to validate the SPV calculation we performed a cross-validation with the volumetric assessment of the skin-adipose paddle according to a mathematical formula ( $SPV = SPA \times SPT$ ), measuring the thickness of the subcutaneous tissue intraoperatively with a ruler. The intraoperative calculated SPV was 177.66 cc (SD 90.05). The cross-validation reported a strong association between the two measurements, with a high Spearman correlation ( $r = 0.718$ ,  $p < 0.001$ ) [Figure 5].

### Predicted calculation of the autologous fat transfer (AFT)

Knowing the volume of the skin and adipose paddle over the LD muscle (SPV) and using the fat-to-capacity ratio described by Del Vecchio et al.,<sup>22</sup> the following formula was



**Figure 4** Correlation between skin paddle thickness (SPT) and BMI. These two values showed a significant association ( $r = 0.640$ ,  $p < 0.0001$ ).

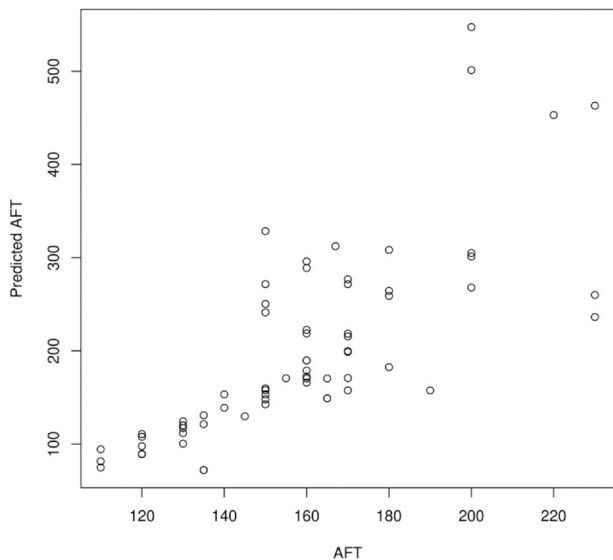


**Figure 5** Correlation between preoperative estimated and intraoperative calculated skin paddle volume (SPV) ( $r = 0.718$ ,  $p < 0.001$ ).

built for the development of the FALD-V (i.e. fat volumetric assessment for LD flap) in order to calculate the optimal amount of fat tissue needed to infiltrate into the FALD flap:

$$\text{FALD-V} = [-509 + 12.32 \times \text{BMI} + 11.71 \times \text{skin paddle width} + 17.43 \times \text{skin paddle height}] \times 1.13$$

The covariates considered in the FALD-V (BMI, skin paddle width and skin paddle height) were statistically significant ( $p < 0.001$ ,  $p = 0.0483$ ,  $p = 0.0154$ , respectively). The  $R^2$  was modest (0.645) and the root mean squared error for the predictions is 53.95. Age did not reach the threshold for statistical significance ( $p = 0.41$ ) and was not included in the predictive formula. Using this formula,



**Figure 6** Predicted and true AFT in the cohort showed good correlation (Spearman's Rho 0.81).

**Table 1** Patients demographics.

|   |   |
|---|---|
| Flaps number                              | 66  |
| Patients number                           | 61  |
| Mean age [y]                              | 54.05 (SD 9.38)                               |
| Mean height [cm]                          | 156.65 (SD 23.85)                             |
| Mean weight [kg]                          | 68.19 (SD 23.44)                              |
| Mean BMI [kg/m <sup>2</sup> ]             | 24.09 (SD 3.78)                               |
| Laterality                                | Unilateral: 56 (91.8%)<br>Bilateral: 5 (8.2%) |
| Skin paddle width [cm]                    | 19.04 (SD 1.59)                               |
| Skin paddle height [cm]                   | 9.67 (SD 1.22)                                |
| Skin paddle area (SPA) [cm <sup>2</sup> ] | 145.12 (SD 26.41)                             |
| Skin paddle thickness (SPT) [mm]          | 11.95 (SD 4.56)                               |

the mean predicted AFT needed per flap was 202.64 cc (SD 80.85), while the mean true intraoperative AFT volume was 158.97 cc (SD 28.85). Predicted AFT and true AFT showed a good correlation (Spearman's Rho 0.81) [Figure 6]. The expected absolute error is estimated as 59.72 cc and the expected relative error is 25.7%. Results are summarized in Tables 1, 2 and 3.

## Discussion

The FALD flap bypasses the limitations of the traditional LD flap, being a totally autologous flap, able to replace breast implants through the intraoperative injection of adipose tissue, although it is considered a second-choice BR procedure after abdominal-based and PAP free flaps.<sup>24-26</sup> Demiri et al. in 2018 described the FALD flap among 47 patient as total BR, despite the need for additional fat grafting sessions.<sup>27</sup> Couto-gonzales et al. in 2020 reported a case series of 95 BR with FALD flap showing excellent esthetic results.<sup>28</sup> Since this reconstructive option is gaining more and more acceptance worldwide, more studies on preoperative planning of the intraoperative autologous fat infiltration are needed.<sup>29,30</sup> Our research group recently published a study on secondary BRs in irradiated breasts using FALD flap, detailing the surgical procedure.<sup>19</sup> Furthermore, in the recent years we have had an evolution regarding orientation of the FALD flap in the recipient breast site. The transition from the traditional transverse/horizontal orientation to the ergonomic vertical orientation of the skin-adipose paddle allowed us to obtain a one-stage reconstruction with superior breast projection, optimal

**Table 2** Operative data.

|                      |                   |
|----------------------|-------------------|
| Flaps number         | 66                |
| Patients number      | 61                |
| Operative time [min] | 266.63 (SD 82.56) |
| Total complications  | 12 (18.18%)       |
| Fat necrosis         | 4 (6.06%)         |
| Seroma               | 7 (10.61%)        |
| Hematoma             | 0 (0%)            |
| Chronic pain         | 0 (0%)            |
| Wound dehiscence     | 0 (0%)            |
| Infection            | 1 (1.51%)         |

**Table 3** Comparison between predicted and intraoperative calculation of SPV and between predicted AFT and true operative AFT. Shown in the right column the Spearman's correlation.

|                                    | Predicted         | Intraoperative    | Spearman r |
|------------------------------------|-------------------|-------------------|------------|
| Skin paddle volume (SPV) [cc]      | 179.33 (SD 71.88) | 177.66 (SD 90.05) | 0.718      |
| Autologous fat transfer (AFT) [cc] | 202.64 (SD 81.22) | 158.97 (SD 28.85) | 0.810      |

upper pole fullness and excellent esthetic outcomes.<sup>31</sup> Regarding thoracodorsal nerve management, unlike what we do in mixed reconstructions with LD flap and breast implant in which we divide the TD nerve, in the case of reconstructions with FALD flap we prefer to leave this nerve intact. Thoracodorsal nerve sparing reduces long-term muscle atrophy and does not affect symptomatic spasticity or involuntary muscle movement as reported by recent studies.<sup>32</sup>

Preoperative planning is essential for all BRs, and even more so in this procedure where a key element is the AFT and the amount of this fat required.<sup>33,34</sup> Knowing preoperatively the exact amount of fat that can be optimally infiltrated into the flap could avoid unnecessary lipoaspirations, shorten OTs while reaching the optimum volume needed in a single procedure. Furthermore, this data would help us to avoid excessive and unsafe infiltrations to the flap, which could affect its perfusion.<sup>35-37</sup> The excessive fat infiltration into the flap could be unsafe for its perfusion as well as counterproductive since an overfilling would lead to the development of oil cysts and fat necrosis.<sup>38,39</sup> We prefer to infiltrate fat tissue orthotopically and not directly into the LD muscles, in order to avoid any risk of potentially fatal embolism and direct or indirect vascular injury and compression of vein perforators,<sup>40</sup> and for the potential adipocytes trans-differentiation into skeletal myocytes.<sup>41</sup>

Del Vecchio et al. in 2014 described the graft-to-capacity ratio dividing the volume of grafted material by the capacity of the breast recipient site.<sup>23</sup> The calculated average graft-to-capacity ratio was 113%, with a standard deviation of 22%. Considering the consistency of breast tissue comparable to subcutaneous tissue of the back, we can estimate that the AFT in the subcutaneous adipose tissue of the FALD skin paddle will be 113% compared to its volume. The information needed to estimate the SPV are all easily available with preoperative measurements, except for the depth of the subcutaneous tissue. So, we calculated this thickness with the fastest, cheapest and least invasive method, i.e. ultrasound scan. Subsequently, we tried to find a relationship between the thickness of the subcutaneous fat tissue of the back and an anthropometric value of our cohort, in order to get the estimated thickness using an easily available measurements in the preoperative period and without any radiological examination. The use of anthropometric data is known to be a fast and cheap method, as well as being easily reproducible, and the value that was most predictive of subcutaneous thickness was BMI, showing a regression coefficient of 0.640 ( $p < 0.0001$ ).

Fujiwara et al. in 2013 firstly described a linear relationship between LD flap weight and BMI, showing that

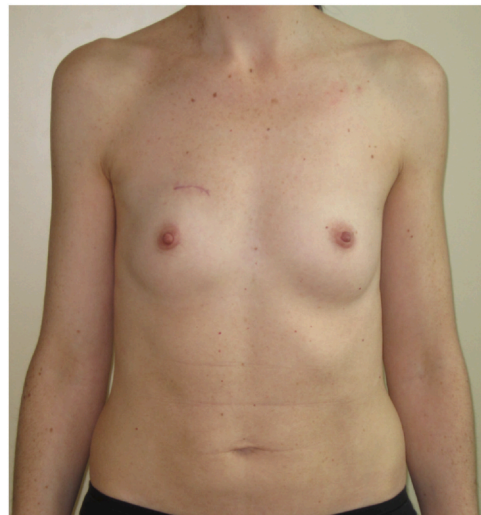BMI had the best correlation with LD flap weight among many variables taken into consideration ( $r = 0.664$ ).<sup>42</sup>

Knowing the exact correlation between BMI and subcutaneous dorsal thickness, the FALD-V predictive formula of the autologous fat needed to be injected into the skin paddle of FALD flap has been developed as described previously:

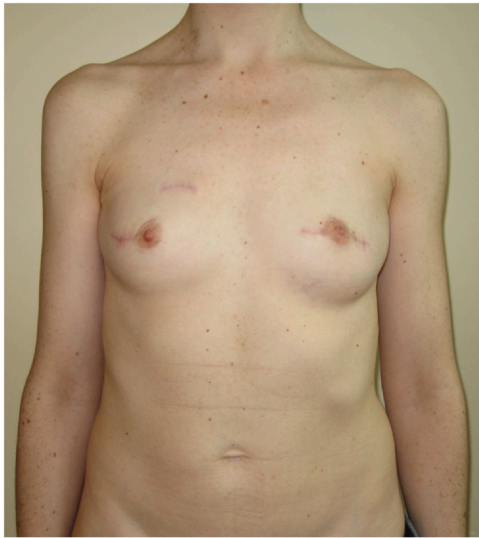$$\text{FALD-V} = [-509 + 12.32 \times \text{BMI} + 11.71 \times \text{skin paddle width} + 17.43 \times \text{skin paddle height}] \times 1.13$$

The FALD-V can be used by reconstructive surgeons very easily in the preoperative period, solely knowing three anthropometric values, or else the skin paddle width, skin paddle height and patient's BMI. To enhance its application and in order to make it accessible to everyone and easy to use, we have developed an 3.0 WebApp at [www.braflap.com](http://www.braflap.com) and [www.BREAST-V.com](http://www.BREAST-V.com) for both iOS and Android devices. The fat tissue survival rate after fat grafting procedures has been described in literature by many authors, and it is widely demonstrated that it is regulated by two fundamental principles: graft-to-recipient interface and interstitial fluid pressure limit.<sup>43,44</sup> Using the graft-to-capacity ratio described by Del Vecchio et al., we can inject adipose tissue minimizing the risk of reducing fat survival rate due to excessive infiltrations.<sup>23</sup>

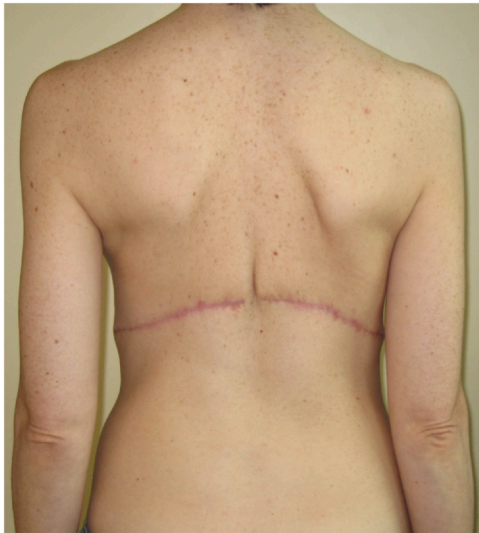During the study the data regarding SPV and predicted AFT remained blinded to the first surgeon (B.L.), who



**Figure 7** Pre-operative photograph (frontal view) of a 45-year-old patient with right breast volume of 104 cc and left breast volume of 114 cc.

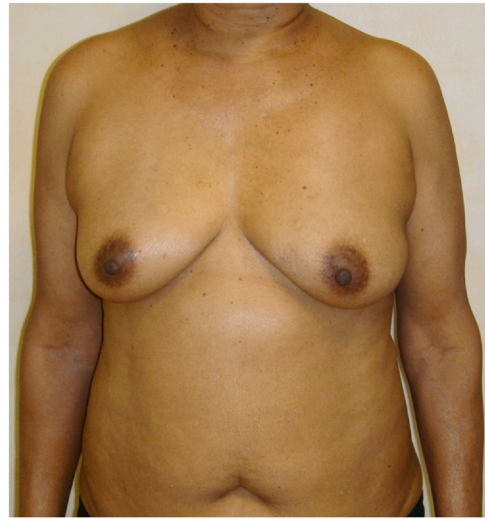

**Figure 8** The same patient (frontal view) 6 months after an immediate bilateral NSM mastectomy and FALD flap breast reconstruction. The estimated SPV was 129.08 cc, while the intraoperative calculated SPV was 120.81 cc, same for both sides. In this case 130 cc of intraoperative AFT was performed on the right breast and 120 cc on the left breast. The calculated AFT with the FALD-V formula was 145.86 cc for both breasts.

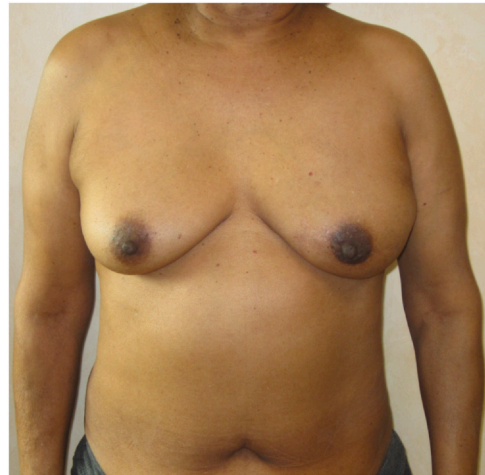

**Figure 9** Post-operative photograph of the donor site, 6 months after the bilateral BR procedure.

performed the intraoperative AFT based on his experience in not overfilling the flap and giving a good breast volume simultaneously. In order to verify the reliability of the described formula, we analyzed and compared the predicted AFT volume needed and true AFT volume performed during surgery. The result of cross-validation reported that the two volumes compared fit well ( $r=0.810$ ) as shown in [Table 3](#) and [Figure 6](#). Furthermore, during the procedure the thickness of the subcutaneous tissue of each flap was measured with a ruler and the SPV mathematically

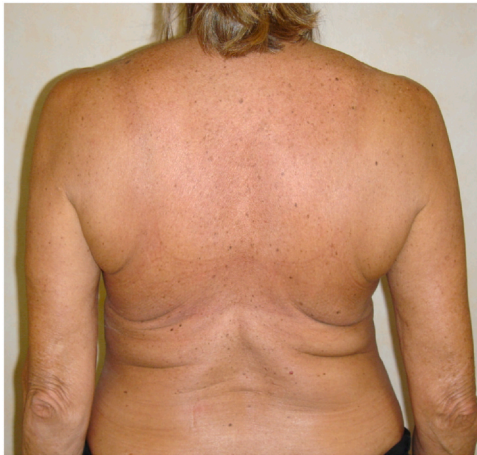

**Figure 10** Pre-operative photograph (frontal view) of a 56-year-old patient scheduled for left breast reconstruction with FALD flap. Preoperative left breast volume = 480 cc.

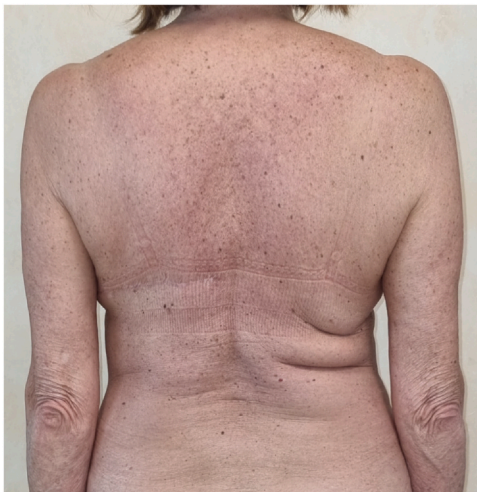

**Figure 11** Post-operative picture 12 months after immediate left NSM with inframammary fold (IMF) incision and breast reconstruction using FALD flap. The estimated SPV was 173.24 cc, while the intraoperative calculated SPV was 181.37 cc. Volume of intraoperative AFT to the left breast = 190 cc. The calculated AFT with the FALD-V formula was 195.77 cc.

calculated. The correlation between predicted SPV and intraoperatively calculated SPV also showed a strong association ( $r=0.718$ ,  $p < 0.001$ ), confirming the accuracy of the formula. The prediction of AFT represents a valid and reliable tool that can be appropriately applied in the pre-operative setting of every FALD flap BR, in order to achieve a safe reconstruction with nice aesthetical outcome as shown in [Figures 7-13](#). Clinically, plastic surgeons can use easily the FALD-V to estimate preoperatively the amount of the AFT needed, as it can speed up the fat aspiration process and avoid excessive and damaging infiltrations for the flap.<sup>45</sup>



**Figure 12** Pre-operative photograph (back view) of a 66-year-old patient scheduled for left breast reconstruction with FALD flap.



**Figure 13** Post-operative picture of the donor site of the same patient, 10 months after left unilateral FALD flap BR.

Using the described formula, it will be possible to calculate during the preoperative marking the precise amount of adipose tissue required to be injected into the skin-adipose paddle of FALD flap, using only three measurements: skin paddle width, skin paddle height and BMI.

## Conclusion

The FALD-V represents a reliable, predictive and reproducible tool that can be used during the preoperative drawing in the planning of a FALD flap one-stage total autologous BR. This innovative device can help plastic surgeons in determining the fat to be aspirated and transplanted, avoiding excessive or insufficient aspirations of adipose tissue, using solely three anthropometric values: skin paddle width, skin paddle height and BMI. To enhance

its application, the FALD-V can be easily used free of charge with a 3.0 WebApp at [www.braflap.com](http://www.braflap.com) and [www.BREAST-V.com](http://www.BREAST-V.com) for both iOS and Android devices.

## Ethical approval

Not required.

## Conflict of interest disclosure statement

We, hereby certify, that to the best of our knowledge no financial support or benefits have been received by author or any co-author, by any member of our immediate family or any individual or entity with whom or with which we have a significant relationship from any commercial source which is related directly or indirectly to the scientific work which is reported on in the article. None of the authors has a financial interest in any of the products, devices, or drugs mentioned in this manuscript.

## Funding

None.

## References

1. Mericli AF, Szpalski C, Schaverien MV, et al. The latissimus dorsi myocutaneous flap is a safe and effective method of partial breast reconstruction in the setting of breast-conserving therapy. *Plast Reconstr Surg* 2019;143(5):927e–35e. <https://doi.org/10.1097/PRS.0000000000005577>.
2. Schonauer F, Cavaliere A, Pezone G, et al. Letter to the Editor in Chief. Thoraco-acromial artery perforator (TAAP) flap for reconstruction of a recurrent dermatofibrosarcoma protuberans of the clavicular region. *PRRS* 1. 2022. p. 79–81. <https://doi.org/10.57604/PRRS-083>.
3. Asaad M, Mitchell D, Murphy B, et al. Surgical outcomes of implant versus autologous breast reconstruction in patients with previous breast-conserving surgery and radiotherapy. *Plast Reconstr Surg* 2023;151(2):190e–9e. <https://doi.org/10.1097/PRS.0000000000009826>.
4. Santanelli di Pompeo F, Laporta R, Sorotos M, Pagnoni M, Falesiedi F, Longo B. Latissimus dorsi flap for total autologous immediate breast reconstruction without implants. *Plast Reconstr Surg* 2014;134(6):871e–9e. <https://doi.org/10.1097/PRS.0000000000000859>.
5. Longo B, D'orsi G, Orlando G, et al. Recurrent dermatofibrosarcoma protuberans of the clavicular region: radical excision and reconstruction with Latissimus Dorsi myocutaneous flap. *PRRS* 2022;1:14–9. <https://doi.org/10.57604/PRRS-002>.
6. Longo B, Di Napoli A, Curigliano G, et al. Clinical recommendations for diagnosis and treatment according to current updated knowledge on BIA-ALCL. *Breast* 2022;66:332–41. <https://doi.org/10.1016/j.breast.2022.11.009>.
7. Villanueva NL, Del Vecchio DA, Afrooz PN, Carboy JA, Rohrich RJ. Staying safe during gluteal fat transplantation. *Plast Reconstr Surg* 2018;141(1):79–86. <https://doi.org/10.1097/PRS.0000000000003934>.
8. Del Vecchio D. Common sense for the common good: staying subcutaneous during fat transplantation to the gluteal region.



- Plast Reconstr Surg* 2018;142(1):286–8. <https://doi.org/10.1097/PRS.0000000000004541>.
9. Ramella V, Stocco C, Grezar L, et al. A new male nipple areolar complex design in trans men chest masculinization. *PRRS* 2022;1:58–63. <https://doi.org/10.57604/PRRS-031>.
  10. Pierazzi DM, Arleo S, Faini G. Combination of LICAP and IMAP flap for treatment of long-lasting cutaneous fistulas of the chest wall with osteomyelitis. *PRRS* 2022;1:20–3. <https://doi.org/10.57604/PRRS-003>.
  11. Demiri EC, Tsimponis A, Pagkalos A, et al. Fat-augmented latissimus dorsi versus deep inferior epigastric perforator flap: comparative study in delayed autologous breast reconstruction. *J Reconstr Microsurg* 2021;37(3):208–15. <https://doi.org/10.1055/s-0040-1716348>.
  12. Campanale A, Ventimiglia M, Minella D, et al. National breast implant registry in ITALY. Competent authority perspective to improve patients' safety. *PRRS* 2022;1:34–45. <https://doi.org/10.57604/PRRS-005>.
  13. Longo B, Giacalone M, D'Orsi G, Gagliano E, Vannucchi L, Ferracci A, et al. Microsurgical reconstruction of lower extremity in homozygosity of C677T MTHFR gene mutation: case report and review of the literature. *Plast Reconstr Regen Surg* 2023;3:98–105. <https://doi.org/10.57604/PRRS-160>.
  14. Longo B, Pistoia A, D'Orsi G, Gagliano E, Vannucchi L, Cervelli V. Lympho-diep flap transfer perfused by reverse-flow thoracodorsal artery: a case report. *Plast Reconstr Regen Surg* 2023;1-2:20–4. <https://doi.org/10.57604/PRRS-326>.
  15. Mazzocchi M, Sigorini G, Cerciello E, et al. The use of Exashape™ Bioshield Pocket in prepectoral breast reconstruction: a preliminary experience. *PRRS* 2022;1:51–7. <https://doi.org/10.57604/PRRS-064>.
  16. Longo B, Timmermans FW, Farcomeni A, et al. Septum-based mammoplasties: surgical techniques and evaluation of nipple-areola sensibility. *Aesthetic Plast Surg* 2020;44(3):689–97. <https://doi.org/10.1007/s00266-020-01657-7>.
  17. Ahmed YS, Abd El Maksoud WM, Sultan MH, El-Bakoury EA. Latissimus dorsi flap enhancement by lipofilling as an immediate breast reconstruction technique for skin-preserving mastectomy. *Breast J* 2021;27(3):222–30. <https://doi.org/10.1111/tbj.14116>.
  18. Longo B, D'Orsi G, La Padula S, et al. Narrow inferior-central septum-based pedicle: a safe technique to improve aesthetic outcomes in breast reduction. *J Plast Reconstr Aesthet Surg* 2023;85:226–34. <https://doi.org/10.1016/j.bjps.2023.07.016>.
  19. Longo B, D'Orsi G, Vanni G, Gagliano E, Buonomo CO, Cervelli V. Fat-augmented latissimus dorsi flap for secondary breast reconstruction in small to medium-sized irradiated breasts. *Plast Reconstr Surg* 2023;152(6):1165–73. <https://doi.org/10.1097/PRS.00000000000010480>.
  20. Longo B, Farcomeni A, Ferri G, Campanale A, Sorotos M, Santanelli F. The BREAST-V: a unifying predictive formula for volume assessment in small, medium, and large breasts. *Plast Reconstr Surg* 2013;132(1):1e–7e. <https://doi.org/10.1097/PRS.0b013e318290f6bd>.
  21. Jouglard J.P.L. (1973) *Plasties Mammaires pour Hypertrophie et Ptose*. Masson et Cie, Paris.
  22. Felici N, Delle Femmine PF, Tosi D, et al. Common peroneal nerve injuries at the knee: outcomes of nerve repair. *PRRS* 2022;1:6–13. <https://doi.org/10.57604/PRRS-001>.
  23. Del Vecchio DA, Del Vecchio SJ. The graft-to-capacity ratio: volumetric planning in large-volume fat transplantation. *Plast Reconstr Surg* 2014;133(3):561–9. <https://doi.org/10.1097/01.prs.0000438471.23249.6e>.
  24. Escandón JM, Escandón L, Ahmed A, et al. Breast reconstruction using the latissimus dorsi flap and immediate fat transfer (LIFT): a systematic review and meta-analysis. *J Plast Reconstr Aesthet Surg* 2022;75(11):4106–16. <https://doi.org/10.1016/j.bjps.2022.08.025>.
  25. Economides JM, Song DH. Latissimus dorsi and immediate fat transfer (LIFT) for complete autologous breast reconstruction. *Plast Reconstr Surg Glob Open* 2018;6(1):e1656. <https://doi.org/10.1097/GOX.0000000000001656>.
  26. Buonomo OC, Vanni G, Materazzo M, Pellicciaro M, D'Orsi G, Meucci R, et al. P196 breast textured implants determine early T-helper impairment: BIAL2.20 study. *Breast* 2023;68:S93–4. [https://doi.org/10.1016/S0960-9776\(23\)00314-4](https://doi.org/10.1016/S0960-9776(23)00314-4).
  27. Demiri EC, Dionyssiou DD, Tsimponis A, Goula CO, Pavlidis LC, Spyropoulou GA. Outcomes of fat-augmented latissimus dorsi (FALD) flap versus implant-based latissimus dorsi flap for delayed post-radiation breast reconstruction. *Aesthetic Plast Surg* 2018;42(3):692–701. <https://doi.org/10.1007/s00266-018-1081-6>.
  28. Couto-González I, Vila I, Brea-García B, et al. Safety of large-volume immediate fat grafting for latissimus dorsi-only breast reconstruction: results and related complications in 95 consecutive cases. *Aesthetic Plast Surg* 2021;45(1):64–75. <https://doi.org/10.1007/s00266-020-01882-0>.
  29. Novak MD, Blough JT, Abraham JT, et al. Breast reconstruction in obese patients: the fat grafted latissimus versus abdominal free tissue transfer. *Plast Reconstr Surg Glob Open* 2020;8(3):e2668. <https://doi.org/10.1097/GOX.0000000000002668>.
  30. Taminato M, Tomita K, Nomori M, et al. Fat-augmented latissimus dorsi myocutaneous flap for total breast reconstruction: a report of 54 consecutive Asian cases. *J Plast Reconstr Aesthet Surg* 2021;74(6):1213–22. <https://doi.org/10.1016/j.bjps.2020.10.089>.
  31. Longo B, D'Orsi G, Giacalone M, et al. The ergonomic FALD flap for one-stage total breast reconstruction. *Plast Reconstr Surg Glob Open* 2023;11(9):e5262. <https://doi.org/10.1097/GOX.0000000000005262>.
  32. Patel R, Oberhofer H, O'Neill D, Samant S, Mast BA. Is thoracodorsal nerve transection needed in latissimus dorsi breast reconstruction? *Ann Plast Surg* 2020;84(6S Suppl 5):S393–5. <https://doi.org/10.1097/SAP.0000000000002281>.
  33. Zhu L, Mohan AT, Vijayasekaran A, et al. Maximizing the volume of latissimus dorsi flap in autologous breast reconstruction with simultaneous multisite fat grafting. *Aesthet Surg J* 2016;36(2):169–78. <https://doi.org/10.1093/asj/sjv173>.
  34. Cervelli V, Longo B. Plastic and reconstructive surgery: roots and future direction of a constantly evolving discipline. *PRRS* 2022;1:49–50. <https://doi.org/10.57604/PRRS-090>.
  35. Hassan AM, Tran J, Asaad M, Slovacek C, Liu J, Butler CE. Outcomes of Third-Attempt Breast Reconstruction following Infection-Associated Failure of Secondary Implant-Based Reconstruction. *Plast Reconstr Surg* 2023;151(3):367e–75e. <https://doi.org/10.1097/PRS.0000000000009903>.
  36. Liu Y, Guo S, Wei S, et al. A novel nitric oxide-releasing gel for diabetic wounds. *PRRS* 2022;1:24–33. <https://doi.org/10.57604/PRRS-004>.
  37. Lovero S, Marchica P, Romeo M, et al. Clostridium septicum fasciitis in a patient with occult colon malignancy: a case report and literature review. *PRRS* 2022;1:69–75. <https://doi.org/10.57604/PRRS-084>.
  38. Chang CS, Lanni MA, Mirzabeigi MN, Bucky LP. Large-volume fat grafting: identifying risk factors for fat necrosis. *Plast Reconstr Surg* 2022;150(5):941e–9e. <https://doi.org/10.1097/PRS.0000000000009655>.
  39. Longo B, D'Orsi G, Pistoia A, et al. T-inverted shaped rectus abdominis myocutaneous (Ti-RAM) flap for chest wall reconstruction. *PRRS* 2022;1:64–8. <https://doi.org/10.57604/PRRS-028>.
  40. Yoshimura K, Coleman SR. Complications of fat grafting: how they occur and how to find, avoid, and treat them. *Clin Plast Surg* 2015;42(3). <https://doi.org/10.1016/j.cps.2015.04.002>.
  41. Kazama T, Fujie M, Endo T, Kano K. Mature adipocyte-derived dedifferentiated fat cells can transdifferentiate into skeletal

- myocytes in vitro. *Biochem Biophys Res Commun* 2008;377(3): 780–5. <https://doi.org/10.1016/j.bbrc.2008.10.046>.
42. Fujiwara T, Yano K, Tanji Y, Kanazawa S, Hosokawa K. Preoperative estimation of pedicled latissimus dorsi flap weight for breast reconstruction. *J Plast Reconstr Aesthet Surg* 2014;67(4):579–81. <https://doi.org/10.1016/j.bjps.2013.11.010>.
43. Khouri RK, Rigotti G, Cardoso E, Khouri Jr RK, Biggs TM. Megavolume autologous fat transfer: part I. Theory and principles. *Plast Reconstr Surg* 2014;133(3):550–7. <https://doi.org/10.1097/01.prs.0000438044.06387.2a>.
44. Khouri RK, Rigotti G, Cardoso E, Khouri Jr RK, Biggs TM. Megavolume autologous fat transfer: part II. Practice and techniques. *Plast Reconstr Surg* 2014;133(6):1369–77. <https://doi.org/10.1097/PRS.000000000000179>.
45. Herbst I, Saltvig I. Cannula tip breakage inside adipose tissue during liposuction - a rare case report. *PRRS* 2022;1:76–8. <https://doi.org/10.57604/PRRS-052>.